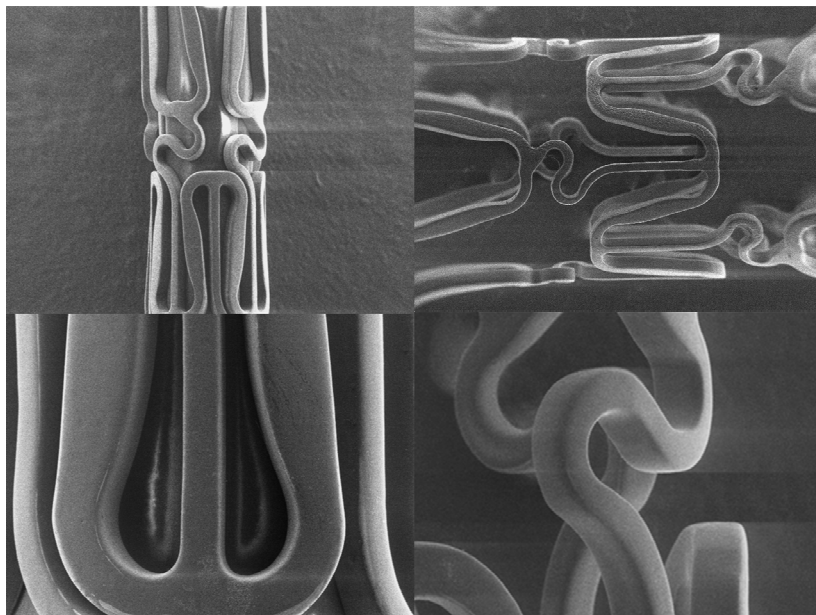


**Novel second generation Paclitaxel-Eluting Biodegradable Polymer Coated Stent  
(LUC-Chopin<sup>2</sup> Balton, Poland)**

**Introduction.** Efficacy of Drug Eluting Stents (DES) to prevent restenosis and to reduce risk of revascularization has been proven in numerous clinical trials. On the other hand, these stents simultaneously inhibit physiological healing process of vessel's wall, lengthen inflammatory reaction and adversely affect the restoration of correctly functioning endothelium. We think that one possible cause for these adverse reactions might be negative influence of permanent presence of polymer used to coat the stent surface and elute the drug.

*We assumed that this scenario can be potentially averted with the use of a biodegradable polymer. Recently, a novel second generation drug eluting stent (LUC-Chopin<sup>2</sup> Balton, Poland) became available on the market which elutes antirestenotic drug- paclitaxel from a biodegradable coating.*

**About the stent.** The Luc-Chopin<sup>2</sup> stent is covered with multi-layer structure containing copolymer of lactic and glycolic acid, paclitaxel and auxiliary substances. Total mass of polymer on a 3.0 x 15 mm stent does not exceed 360 µg. In-vitro evaluations suggest that the coating degrades entirely in eight weeks. Analysis of Luc-Chopin<sup>2</sup> stent's surface structure before and after expansion shows uniform coating without peeling or fractures. Paclitaxel in dose 1,0 µg/mm<sup>2</sup> was chosen as a drug inhibiting neointimal proliferation.



*Excellent coating integrity of LUC-Chopin<sup>2</sup> stent.*

*In First-In-Man feasibility multicenter registry performed in Poland we have included 116 patients and confirmed, clinically and angiographically, the high safety profile and efficacy of the LUC-Chopin<sup>2</sup> stents in treatment of coronary lesions.*

**First-In-Man registry**

**Methods.** Adult patients (>18 years) with symptomatic coronary artery disease who had single „de novo” lesions (>50% DS) in native coronary arteries were enrolled to the study. Patients with contraindications to receive antiplatelet therapy, with active ulcer disease, hemorrhagic diathesis and non-cardiac disease, which could limit long-term survival, were excluded from study. Ostial lesions, unprotected left main disease or total occlusions were also excluded. Dual oral antiplatelet treatment was continued for 6 months. Percutaneous coronary intervention was performed using standard techniques. Predilation was not obligatory and depended on operator’s preferences. All angiograms were recorded digitally in DICOM format and subjected to analysis at an independent core laboratory (KCRI, Krakow, Poland).

**Primary endpoints.** Primary endpoints of study were angiographic features of restenosis in stented segments, evaluated in the 9-month follow-up coronary angiography, and clinically driven revascularization of the study stent including 5 mm margins (target lesion revascularization, TLR) in 12-month clinical observation. Clinically driven TLR was defined as: any stenosis > 70 % in target lesion or stenoses between 50 - 70 % in target lesion accompanied by stenocardial signs or symptoms.

**Demographic data.** Average age of studied population was  $54 \pm 21$  years. Stable angina was present in 85.2% patients and diabetes in 21.7%. More demographic data of the studied population are showed in table.

Table 1. Demographic data

	n [%]
Male	85 [73,9 %]
Hypercholesterolemia	69 [60,0 %]
Smoking	65 [56,5%]
Diabetes	25 [21,7 %]
Hypertension	80 [69,5 %]
Previous myocardial infarction	43 [37,4 %]
Stable coronary disease	98 [85,2 %]
Unstable coronary disease	15 [13,0 %]
STEMI, NSTEMI	2 [1,8 %]

**Procedural outcomes.** Eighty one procedures (70,4%) were accomplished with direct stenting and 34 (29,5%) with predilation. In 78 procedures (67,8%) additional postdilation was done. Lesions characteristic and their localization are presented in Table 2.

Table 2. Lesions characteristic.

		n	%
Disease	Single-vessel	52	45,2
	Double-vessel	56	48,7
	Tri-vessel	7	6,1
Lesion type	A	12	10,4
	B <sub>1</sub>	49	42,6
	B <sub>2</sub>	45	39,1
	C	9	7,9

**Long-term results.** Angiographic restenosis rate was low (9,9 %) for all lesions (including small vessels) assessed after 9-month. Additionally there were two cases with borderline stenosis of ca 50 %. More detailed analysis is presented in Table 3.

Table 3. Restenosis rate for LUC-Chopin stents\_subanalysis.

	Restenosis rate
3,0 – 4,0mm	6,8%
2,8 – 4,0mm	9,5%
All lesions (<2,8 – 4,0mm)	9,9%
Including two cases with borderline stenosis (ca 50%)	11,9%

The mean late loss for tested stents was  $0,46 \pm 0,47$  These results are satisfactory in view of rather complex lesions (47% were AHA class B2 and C).

What important, during 12-months follow-up there was no occurrence of death, stroke or necessity for surgical revascularization (CABG). Two cases of myocardial infarction occurred (1,9%). One was related to recent subacute stent thrombosis and another to restenosis. However, the early stent thrombosis was subacute and therefore did not seem to be related to degradation of coating, which is projected to last at least 8 weeks. Moreover, during observation time after Luc-Chopin<sup>2</sup> implantation, low revascularization rate in stented vessels segments (TLR = 7,0 %) was observed and only 3 of these patients (2,6 %) have had re-intervention caused by refractory angina (chest pain). In the remaining 6 patients coronary angioplasty was primarily driven by angiographically confirmed restenosis at 9-months follow-up.

Table 4. Clinical events at 12 months follow-up.

	No. of patients	% of patients
Death	0	0
Myocardial infarction	2	1,9
Stroke	0	0
Thrombosis	1	0,9
- during hospitalization	1	0.9
- since discharge to 12 months	0	0
TLR before planned coronarography	3	2,6
MACE before planned coronarography	3	2,6
TLR based on control coronarography	5	4,9
TLR (all)	8	7,0
MACE (all)	9	7,8

The restenosis pattern was mild overall, with majority of affected patients showing stenosis of 50-70 %. Only in two cases stenosis was more then 70 %. There was no occlusive nor proliferative restenosis.

**Summary.** This first-in-man experience obtained in a multicenter registry of real world lesions treated with a novel LUC-Chopin<sup>2</sup> stent eluting paclitaxel from bioabsorbable polymer has been positive overall. Safety profile appeared excellent and we did not observed incidents of late stent thrombosis between 30 and 365 days of clinical follow-up. This is always encouraging for a new DES concept in view of recent concerns about excess late events with DES. Angiographically documented restenosis was comparable to previous experiences with paclitaxel and ischemia-driven revascularization rate was low.

Conceptually, use of biodegradable polymer whose duration on the stent surface matches the period of antirestenotic action of the drug may provide improved safety profile by reducing late events related to persistent presence of polymer on the surface of the first-generation stents. It may consequently also shorten the obligatory period of double antiplatelet therapy, enhancing overall clinical and economical benefit. Therefore, this stent can be preferred in patients with increased risk of bleeding (elderly) or in patients scheduled for a surgery.